

Total hip arthroplasty for the treatment of severe hip osteoarthritis due to fluorosis

Su Wei-min¹, Liu Ri-guang¹, Ye Chuan¹, Yu Yan-ni², Guan Zhi-zhong²

Abstract

BACKGROUND: Now, total hip arthroplasty (THA) is one of the effective methods for the treatment of severe hip osteoarthritis due to fluorosis.

OBJECTIVE: To investigate the strategies and efficacy of THA for the treatment of severe hip osteoarthritis due to fluorosis.

METHODS: A total of five cases with severe hip osteoarthritis due to fluorosis were treated with THA using biological prosthesis.

RESULTS AND CONCLUSION: All incisions were healed in one stage. Position of the prosthesis was good confirmed by X-rays observation at 1 week after operation. All the cases were followed-up for averagely 13.8 months. Loosening and sinking of the prosthesis were not found during the follow-up. The average Harris scores were 83.6 and 87.8 points at postoperative 3 and 6 months respectively, which was improved as compared with preoperative score (38.4 points). Heterotopic ossification occurred in two cases, one was Brooker degree I and another was degree II. THA is an effective method to treat severe hip osteoarthritis due to fluorosis, which can significantly improve joint function and has few complications. Heterotopic ossification should be prevented after the operation.

Su WM, Liu RG, Ye C, Yu YN, Guan ZZ. Total hip arthroplasty for the treatment of severe hip osteoarthritis due to fluorosis. *Zhongguo Zuzhi Gongcheng Yanjiu*. 2012;16(9): 1543-1546. [http://www.crter.cn http://en.zglckf.com]

¹Department of Orthopedics, Hospital of Guiyang Medical College, Guiyang 550004, Guizhou Province, China; ²Guiyang Medical College, Guiyang 550004, Guizhou Province, China

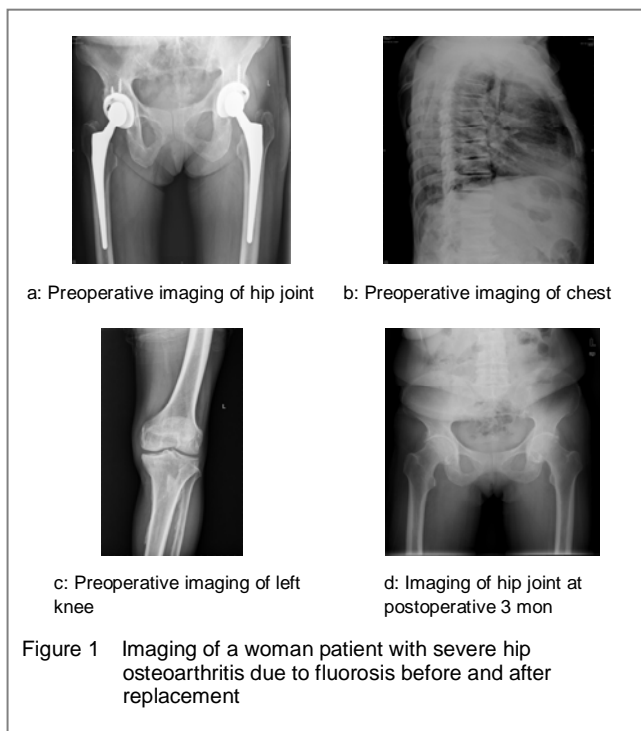
Su Wei-min★, Studying for master's degree, Attending physician, Department of Orthopedics, Hospital of Guiyang Medical College, Guiyang 550004, Guizhou Province, China swm931142625@163.com

Correspondence to: Liu Ri-guang, Doctor, Chief physician, Professor, Master's supervisor, Department of Orthopedics, Hospital of Guiyang Medical College, Guiyang 550004, Guizhou Province, China liuriguang5629519@tom.com

Supported by: Major Project of International Scientific and Technological Cooperation, No. 2010DFB30530*

Received: 2011-11-22 Accepted: 2011-12-29

Tables and figures



REFERENCES

- [1] Li XH,Zhang XL.Zhongguo Difangbing Fangzhi Zazhi. 2006;21(4): 215-217.
- [2] WHO.Fluoride and Human Health. Geneva:WHO Expert Series, 1971:59.
- [3] Song YC, Meng QC,Fang R,et al.Zhongguo Zuzhi Gongcheng Yanjiu yu Linchuang Kangfu. 2009;13(35):6845-6849.
- [4] Huang CQ. Zhongguo Difangbing Xue Zazhi. 2010;29(2) : 231-233.
- [5] Huang CQ,Wang CH,Zhang XL,et al.Zhongguo Difangbing Xue Zazhi. 2005;24(1): 64-66.
- [6] Chen LY,Wen XL,Wang Y,et al.Yixue Yanjiu yu Jiaoyu. 2010;27(3): 54-56.
- [7] Li GS. Zhongguo Difangbing Xue Zazhi. 2006;25(2):119-120.
- [8] Waldbott GL.Symposium on the Non-Skeletal Phase of Chronic Fluorosis.Fluoride.1976;9(1): 5-8.
- [9] Franke J,Rath F,Runge H,et al.Industrial Fluorosis. Fluoride. 1975;8(2): 61-83.
- [10] Gao HX,Dai GJ,Zhang XX,et al. Zhongguo Difangbing Xue Zazhi. 2001;20(1): 31-32.
- [11] Liu XQ. Zhongguo Difangbing Xue Zazhi. 2000;19(5):394.
- [12] Dai GJ,Zhai C,Gao HB,et al. Zhongguo Difangbing Xue Zazhi. 1997;16(4): 234.
- [13] Grandjean P,Thomsen G.Reversibility of Skeletal fluorosis. Br J Ind Med. 1983;40(4):456-461.